

Tikrit University

College of Nursing

Basic Nursing Sciences



First Year [REDACTED]

Anatomy

first stage

(عنوان المحاضرة)

Muscular system(Head, neck, chest and abdomen)

by:

Asst. Lecturer:

Noor Mokhlis Hamed

Muscles of the Head and Neck :

Humans have well-developed muscles in the face that permit a large variety of facial expressions. Because the muscles are used to show surprise, disgust, anger, fear, and other emotions, they are an important means of nonverbal communication.

Muscles of facial expression include :

1. Frontalis.
2. Orbicularis oris.
3. Orbicularis oculi.
4. Buccinator.
5. Zygomaticus.
6. Orbicularis oculi.

These muscles of facial expressions are identified in the illustration below.

There are four pairs of muscles that are responsible for chewing movements or mastication. All of these muscles connect to the mandible and they are some of the strongest muscles in the body.

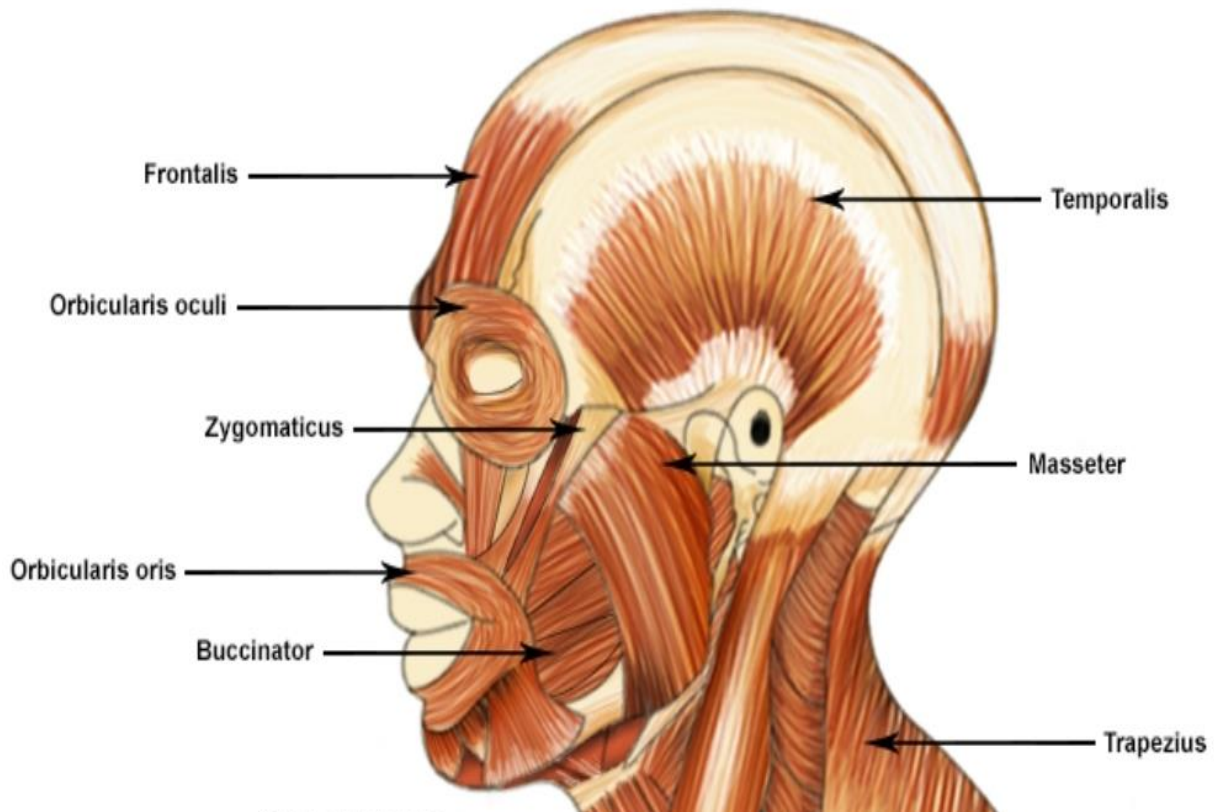
Two of the muscles identified in the illustration above are :

1. Temporalis.
2. Masseter,

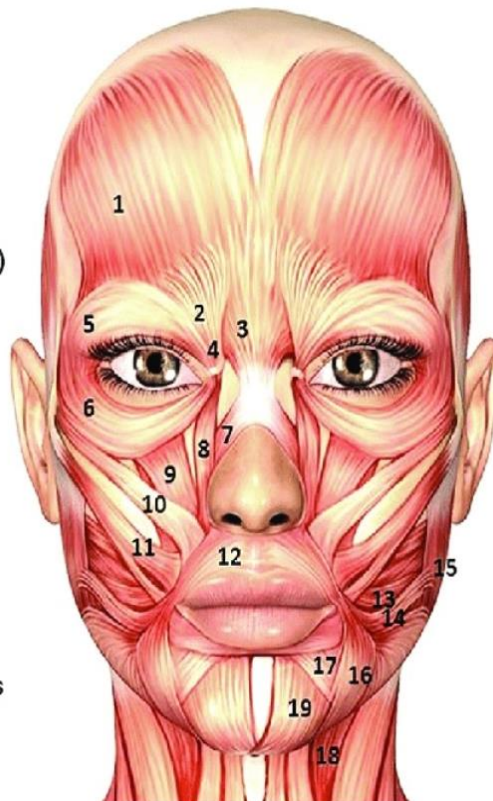
There are numerous muscles associated with the throat, the hyoid bone and the vertebral column; only two of the more obvious and superficial neck muscles are identified in the illustration:

1. Sternocleidomastoid.
2. Trapezius.

Muscles of the Head and Neck



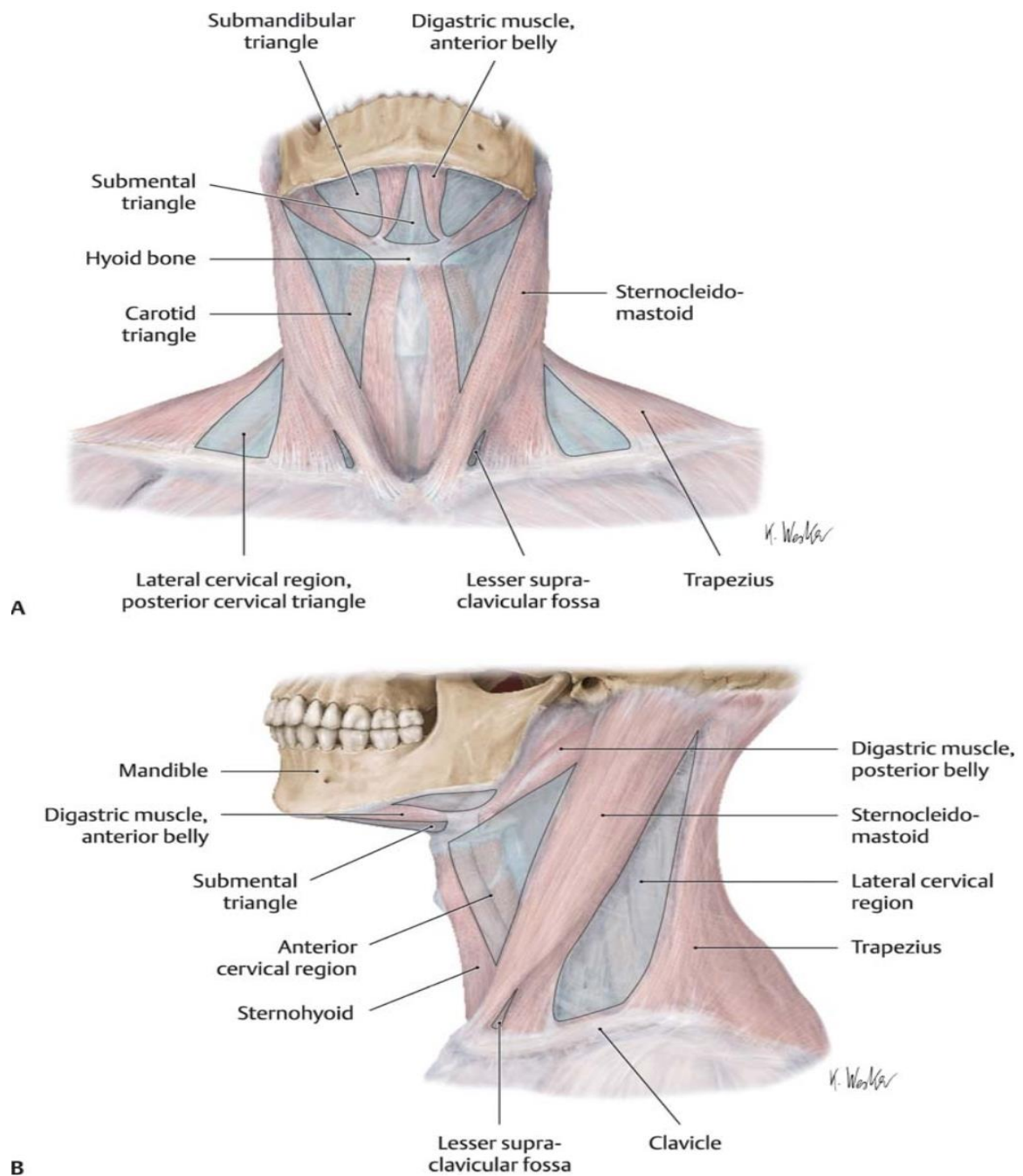
1. Frontalis
2. Corrugator supercilii
3. Procerus
4. Depressor supercilii
5. Orbicularis oculi (superior lateral)
6. Orbicularis oculi (lateral)
7. Nasalis
8. Levator labii superioris alaeque nasi
9. Levator labii superioris
10. Zygomaticus minor
11. Zygomaticus major
12. Orbicularis oris
13. Buccinator
14. Risorius
15. Masseter
16. Depressor anguli oris
17. Depressor labii inferioris
18. Platysma
19. Mentalis



Muscles of the Neck :

Major Neck Muscles

1. Levator Scapulae :connects the top/back of the shoulder blade to the skull.
2. Sternocleidomastoid :primary superficial muscles, connects the top of the sternum to the mastoid process of the temporal skull (side of skull).
3. Scalene muscles :connects C2-C7 to the upper and second ribs lateral to the spine.
4. Digastric muscles :connects throat to chin.



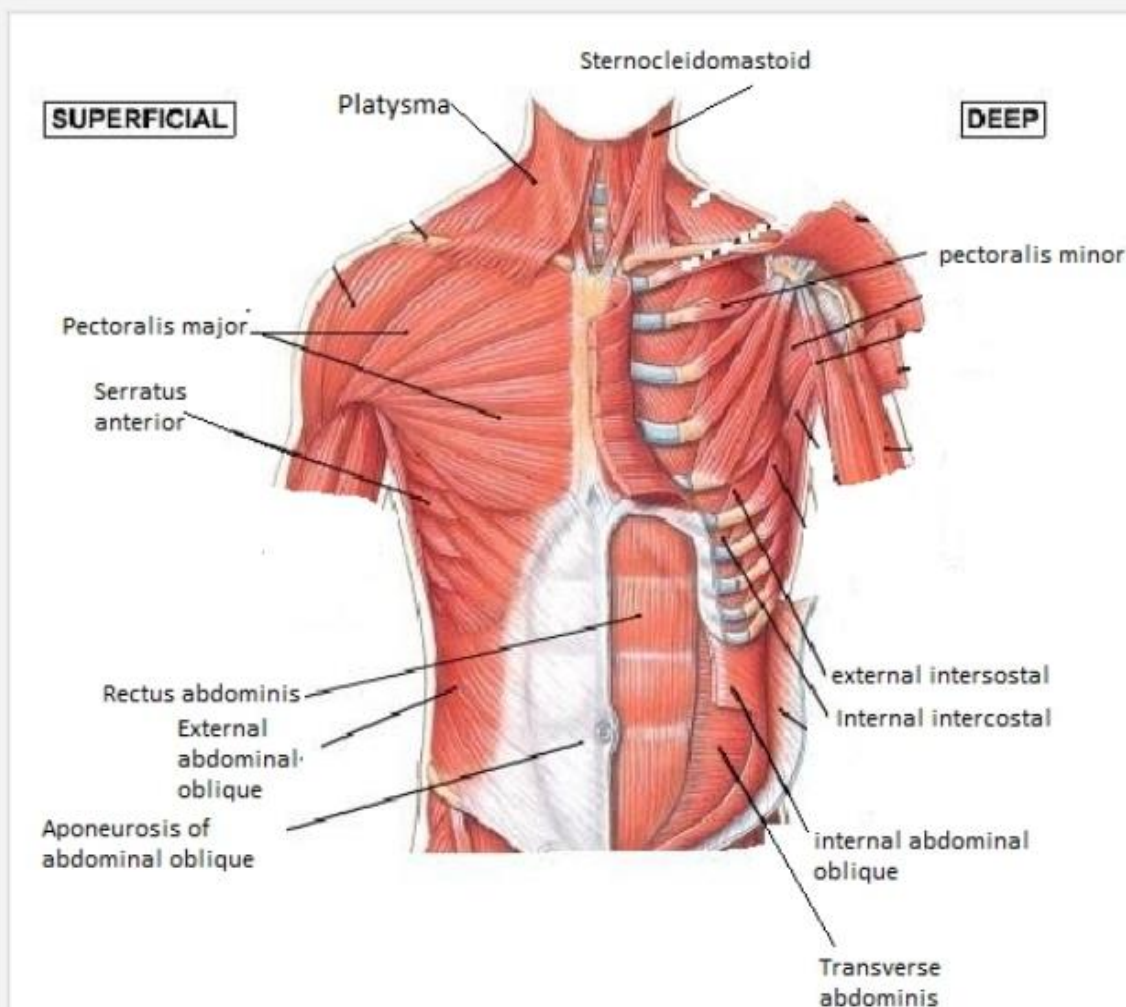
Chest and abdomen muscles :

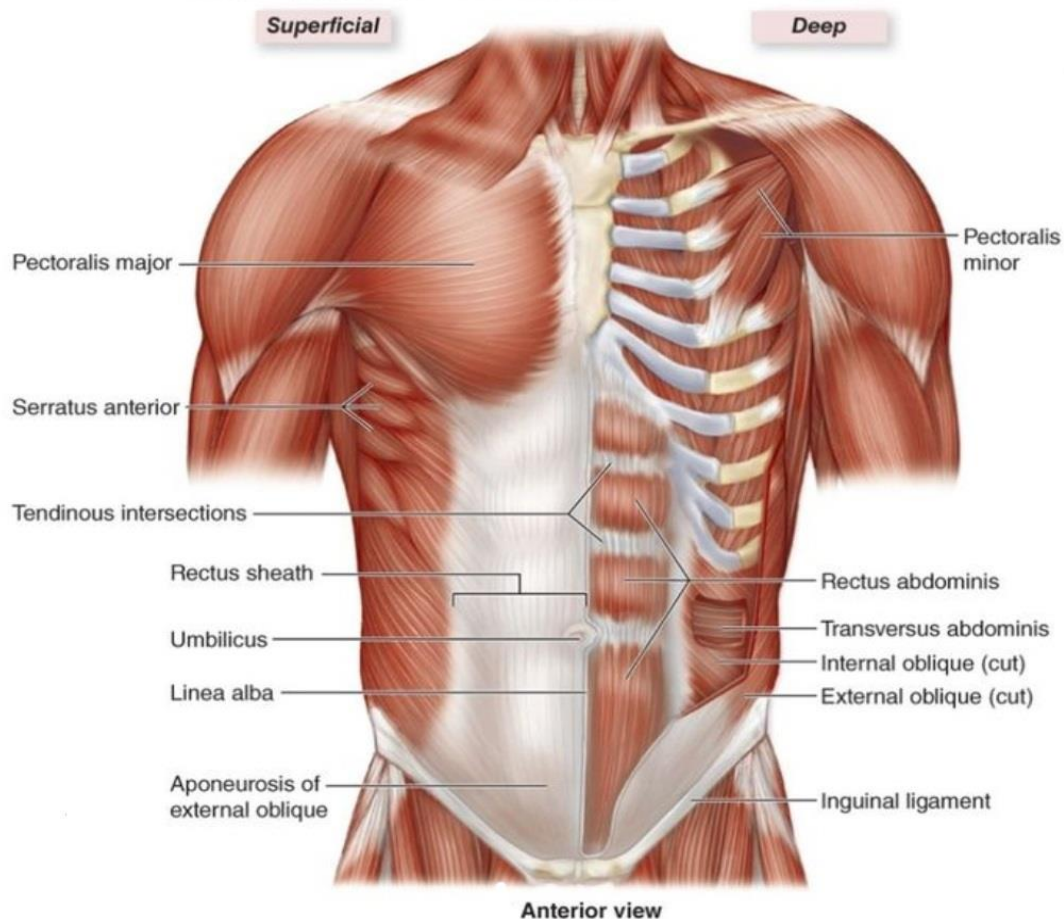
The chest and abdominal muscles are the muscles forming the abdominal walls, the abdomen being the portion of the trunk connecting the thorax and pelvis. An abdominal wall is formed of skin, fascia, and muscle and encases the abdominal cavity and viscera.

The abdominal muscles support the trunk, allow movement, hold organs in place, and are distensible (being able accommodate dynamic changes in the volume of abdominal contents).

The deep abdominal muscles, together with the intrinsic back muscles, make up the core muscles and help keep the body stable and balanced, and protects the spine.

Muscles of the Anterior Chest and Abdomen





Causes of abdominal muscle strains include overstretching, overuse or a violent, poorly performed movement of the trunk, improper technique while playing sports that require running, turning, and jumping, lifting heavy objects, laughing, coughing, or sneezing.

When people think of abdominal muscles it is these four main muscles

1. Transversus abdominis – the deepest muscle layer. Its main roles are to stabilise the trunk and maintain internal abdominal pressure.
2. Rectus abdominis – slung between the ribs and the pubis at the front of the pelvis. When contracting, this muscle has the characteristic bumps or bulges that are commonly called ‘the six pack’. The main function of the rectus abdominis is to move the body between the ribcage and the pelvis
3. External oblique muscles – these are on each side of the rectus abdominis. The external oblique muscles allow the trunk to twist, but to the opposite side of whichever external oblique is contracting. eg the right external oblique contracts to turn the body to the left.
4. Internal oblique muscles – these flank the rectus abdominis and are located just inside the hipbones. They operate in the opposite way to the external oblique muscles. eg

twisting the trunk to the left requires the left side internal oblique and the right side external oblique to contract together.